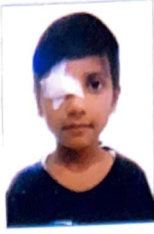

**ALL INDIA INSTITUTE OF MEDICAL SCIENCES
DR. RAJENDRA PRASAD CENTRE FOR OPHTHALMIC SCIENCES
ANSARI NAGAR, NEW DELHI-110029
Medical Social Service Unit, Phone:- 011-26593092,26593027**



UHID	105064247		
Patient's Name	RIDDHI		
S/D/W/of	PINTU SHARMA		
Age	7Y	Sex	F
Address	414 PATTHAR GALI NAKHAS KONA SHAHGANJ, UP		
State	DELHI		
Contact No:-	9695428482		
Card Status/BPL/APL/AAV	ND	Card No :	
Family Income	6,000/-		
Source of Income	MASON		
Diagnosis	https://www.childhelpinghand.org		
Treating Doctor	DR. LOME		
Treatment Required	Treatment Completed		
Expenditure Estimated	17,000/-		
Assistance required for Surgical Item/Medicines/Spect./Lense.	Artificial Eye		
Remarks	Patient is very poor they need support for Artificial eye		

Enclosures:-

1. OPD Card(Treatment Card)	2. Estimate	3. Identity Proof
------------------------------	-------------	-------------------

Applicant's Name RIDDHI
 Relation With Patient..... FATHER

Funding Agency /Donor Name..... CHILD HELPING HAND NGO

डॉ. निवेते लोम / Dr. NEIWETE LOMI
 सहायक आचार्य / Assistant Professor
 डॉ राजेंद्र प्रसाद नेत्र चिकित्सा केंद्र
 P. Center for Ophthalmic Sciences
 आ.आ. नई दिल्ली / A.I.I.M.S., New Delhi-29

[Signature]
 6/9/2024

ब० रो० वि० कार्ड
O.P.D. Card



अनुपाग व दिन
Section and Day **VI**
बुधवार व शनिवार
Wednesday & Saturday

कमरा नंबर
Cabin No. **26/2/20**

डा० राजेन्द्र प्रसाद नेत्र विज्ञान केन्द्र

DR. RAJENDRA PRASAD CENTRE FOR OPHTHALMIC SCIENCES

अ० भा०
Dr. Rajer
A.I.I.M.S.

UHID: 10506424
Dept No 20200050015352
RIDDHI
D.O: PINTU SHARMA

Date: 25.02.2020
RPC OPD-Dr. NEIWETE
OMI
Unit: VI
WED. SAT
Room No.: 32

यु एच आ
UHID N

एकक
Unit

Nar

Address: 44 PATTHAR GALI NALHASKI, NA SHAHGANGI, UTTAR
PRADESH, INDIA
Mobile: 9697428482

पता
Address



दिनांक DATE	निदान DIAGNOSIS
	उपचार Treatment
26 FEB 2020	<p>① <i>frunled</i> https://www.childhelpinghand.org <i>7th floor</i> <i>select</i> <i>HPK report - path lab</i> <i>on 18/2/2020</i> <i>Mo HRE</i> <i>bed mil floxer</i> <i>000</i> <i>ad Report tea</i> <i>over</i></p>
	<p><i>Mo HRE</i> <i>report</i> <i>report</i></p>

कार्ड को सुरक्षित रखें तथा अस्पताल में दिखाने के समय हम वक्ता माथा लागे।
Kindly keep this Card safely and bring it on your follow up visits.

- धूम्रपान निषेध
- कूड़ा कर्कट केवल कूड़ेदान में ही डालें
- थूकिये नहीं

दिनांक - Date

उपचार- Treatment

(R)

4 MAR 2020

धुन धुन 1 मिनट

4 mil-flolex 000

<https://www.childhelpinghand.org>

ad up for 000 (R)

(34A)

data for EVA x 1 minute

(16)

Details (L)

4/3/2020

EVA:

17/04/20

R.No 63, 8am

NPO from 2am for hold

form for hand

(115)

Artificial eye

VH-26h (L)

नेत्र ईश्वरीय सर्वश्रेष्ठ उपहार है जिनका प्रमुख जीवन में दान करना परमश्रेष्ठ है।

इनकी पुर्ण रक्षा कीजिए ताकि ये आपकी रक्षा कर सकें।

Eyes are God's most precious gift to man kind. Take full care of them

So that they can take care of you

Discharge Report
 - PROVISIONAL DISCHARGE CERTIFICATE

20-270
 18/2/20

Unit No: 10064247 Cr No: H 006770-20
 Name: Miss RIDDIH RIDDIH Department: R. P. Centre (Eye Centre)
 Age/Sex: 6 years, 14 days / Female Unit: Unit-VI
 Ward Name: 1A Bed No.: 122
 Address: 4/4 PAITHAN GALI NAKHAS KONA SHAHGANI, UTTAR PRADESH, INDIA
 Mobile No: 9695428482
 Date of Admission: 15/02/2020 10:41:24 AM
 Date of Discharge: 19/02/2020 10:29:00 AM

Drug Allergy, if any :- []

ICD Code: A69.2
 ICD Description: Malignant neoplasm Retina

R.E Silicone implant of size 20mm
~~size~~ - 11mm
 optic nerve stump.

Diagnosis
 R: GROUP E RB
 L: WNL

Investigation
 Systemic: NO SE
 Ocular: VA RE NOT FOLLOWS LG-H
 I.E. 6/6
 IOP RE DIGITALLY NORMAL
 I.E. DIGITALLY NORMAL

Treatment/Operative Procedure
 Surgeon: DR LOMI
 Date: 18/02/2020

Surgery: RE ENUCLEATION UNDER GA
 & TOR COMPLEXITY & myo conjunctiva technique.

Condition at Discharge
 Vision: RE 4/60
 Anterior Seg: RE
 Posterior Seg: RE

<https://www.childhelpinghand.org>

Advice During Discharge
 Oral: SVP ALBIMINTIN 5 ML TDS
 SVP JBUGENIC 5 ML TDS
 SVP OMNACORTEL 15 ML QD
 SVP DIGENE 5 ML BID
 Follow Up: WITH DR LOMI AFTER 1 WEEK IN R.N. 32 ON
 WED/ SAT AT 9AM

Topical: RE
 Position: RE
 10000

& histopath report from 7th floor. (ocular pathology)

32

EUA - R.E group E RB
 L.E WNL

Signature: [Handwritten Signature]

Prepared By: Dr. [Handwritten Name] Ophthalmology

Signature Of Senior Resident

Date & Time

MRI - normal posterior eye cavity & NO optic nerve involvement

Histopathology Report

Ocular Pathology

Dr. Rajendra Prasad Centre for Ophthalmic Sciences

All India Institute of Medical Sciences

Ansari Nagar, New Delhi - 110029, India



Name of the Patient: Riddhi

Lab Reference No. : 20-270

Age : 6 Years Sex : Female

Received on : 18/2/2020

UHID No. : 105064247

Date of Report : 4/3/2020

Ward IA

Bed No. : 122


Unit Incharge : Prof. Tandon.

Nature of the Material Submitted : Enucleation.

Report :

- Enucleated right eyeball.
- Poorly differentiated retinoblastoma.
- All the tissues including ciliary body, choroid and optic nerve including its resected margins are free of tumour.

<https://www.childhelpinghand.org>


Reported By 
Consultant : Dr. Seema Sen

मैं पिंस कुमार शर्मा मेरी बेटी का नाम रिही शर्मा है
 मैं जिसका समाज DEWA AIMS RPE से चल रहा है।
 मैं पप देवीपुर पंचर गली, धाना - शाहगंज जिला प्रयागराज का
 रहने वाला हूँ मैं अत्यंत गरीब हूँ।
 मैं सधुमर या जिसका समाज के दौरान से निकाल दिया
 गया है मेरी वार्षिक आय 72,000 है मैं सच्ची बेचन का
 काम करता हूँ।
 रिही को जकाली और लगावनी है जिसके लिए
 मुझे आर्थिक सहायता की आवश्यकता है।

कृपया मेरी मदद करे जिसके लिए मैं
 आपका सदा आभारी रहूँगा।

धन्यवाद
<https://www.childhelpinghand.org>

- पिंस कुमार शर्मा
 - अमिता शर्मा
 (अनीत शर्मा)


 24/09/2024