



नगर का पता - "मेडिन्स्ट"
TELEGRAM - "MEDINST"

दूरभाष : २६५८८५००, २६५८८७००, २६५८६६००
Telephones : 26588500, 26588700, 26589900

अखिल भारतीय आयुर्विज्ञान संस्थान
ALL INDIA INSTITUTE OF MEDICAL SCIENCES
अन्सारी नगर, नई दिल्ली-११००२६ (भारत)
ANSARI NAGAR, NEW DELHI - 110029



**ESTIMATE CERTIFICATE
TO WHOM IT MAY CONCERN**

संदर्भ सं० / Ref. No.....

दिनांक / Date 13/09/2024

This is to certify that Shri/Ms. Naksh Goswami Age 2.5 yrs Gender M

S/o,D/o,W/o Avineesh Goswami is getting treatment under Dr. Rashika Tandon Dept.

Wide registration no. UHID No. 104949885

is suffering from Retinoblastoma

He/She has been advised for Medicine/Surgery/Surgical items/procedure/package and the approximate

Cost of the total treatment is amount to Rs 64,650/-

(in words) Rupees Sixty four thousand six hundred & fifty.

Item-wise break-up of expenditure of the estimate (if applicable) is as below.

Cost in Rs.

Item No.	Item Description	Cost in Rs.
1.	Inj. Omnipaque	₹ 1000
2.	Inj. Nimodipine	₹ 1000
3.	Inj. Melfalan	₹ 2500
4.	Inj. Topotecan	₹ 4000
5.	Inj. Carboplatin	₹ 2000
6.	Miraj	₹ 12,000
7.	Marathan	₹ 28,000

8.	PMO line	₹ 1000
9.	Percutaneous arterial sheath	₹ 1000
10.	ECG electrodes - 20	₹ 1000
TOTAL COST: Rs		₹ 64,650/-

Note: # This Estimate certificate is being issued to avail financial assistance for treatment only.

The said estimate certificate is valid and applicable for avail financial assistance from Rastriya Arogya Nidhi (RAN), Delhi Arogya Nidhi (DAN), State Illness assistance fund, Prime Minister's Relief Fund, Health Minister's Discretionary Fund (HMDF), MP local area development fund, CM relief fund, and fund from other sources.

This Estimate Certificate is also applicable for Govt./PSU's employees and beneficiaries of ESI

The Cheaque is to be issued in favor of "Director AIIMS, New Delhi".

11. IV Infusion set (B. Braun) ₹ 50
12. Short connecting tube 3way ₹ 50
13. long connecting tube 3way ₹ 80
14. Medicut Puncture needle 21G - ₹ 50
15. Double large bore Y connector ₹ 100
16. Exchange Guidewire (TERMO) 180cm 0032 angled - ₹ 1800
17. FN VIV SF - ₹ 11,300

डॉ. नवीते लोमी / Dr. NEIVETE LOMI
अध्यक्ष, अखिल भारतीय आयुर्विज्ञान संस्थान, नई दिल्ली
Asstt. Prof. of Ophthalmology
नेत्र विज्ञान केंद्र
All India Institute of Medical Sciences
New Delhi-29

(Name & Signature of Consultant with Stamp)

दिनांक - Date

Date for EOA

उपचार - Treatment

Dilem 116 121E

20/12/19

Room no 63, 8wocm

NPO $\left\{ \begin{array}{l} \text{Solid - 3am} \\ \text{Liq - 6am} \end{array} \right.$

(136) USG PSE (R)

specificity. n/o pb.
RD.

s/o retinal mass
& calcification
& RD, > 50% of
vitreal
s/o

(R) retinoblastoma

Obtain my eye -
ocular oncology
opinion

Dilem 115

29m 115

MRI brain
& orbit

contrast enhanced
& fats suppressed

in Axial / coronal / sagittal
section & 2mm cuts
permif through optic
nerve & paranasal
funds

- May Thomas NRC review

Date for EOA
5th Jan

11/12/19 नेत्र ईश्वरीय सर्वश्रेष्ठ उपहार है जिनका मनुष्य जीवन में दान करना परमश्रेष्ठ है।
इनकी पूर्ण रक्षा कीजिए ताकि ये आपकी रक्षा कर सकें।

Eyes are God's most precious gift to man kind. Take full care of them
So that they can take care of you

Kevin

mini report
used for
#53

ब० रो० वि० कार्ड
O.P.D. Card



अनुभाग व दिन
Section and Day

VI

कमरा नंबर
Cabin No.

DR. RAJENDRA PRASAD CENTRE FOR OPHTHALMIC SCIENCES

UHID: 104949855
Dept. No.: 20190050157398
NAKSH GOSWAMI 2Y/M
S/O: AVINESH GOSWAMI

Date: 11/12/2019
General ₹10
RPC OPD-Dr. SR/JR
UNDER UNIT-VI R.34B
Unit-VI WED, SAT
Room No.: 34B

Address: 27, AZAD NAGAR BELKAR ALWAR, RAJASTHAN, INDIA
Mobile: 9772583292



रोगी का नाम
Name of the patient

दिनांक
DATE

निदान
DIAGNOSIS

उपचार Treatment

वर्तमान - not follows
follows objects
Recurr. cyclin
R eye on Tech light DDD.
ED DE

Ⓡ eye noticed: 10-15 days

leucomas

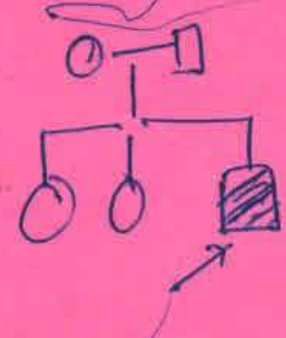
pupils RAPD

Recurr. A/C

FT
C-sect
H/O jaundice
H/O NICU relm...
fr 3 days.
Pnd wt → NR

Frnd White m...

Mixt m...
br...



कृपया इस कार्ड को सुरक्षित रखें तथा अस्पताल में दिखाने के समय हर वक्त साथ लायें।
Kindly keep this Card safely and bring it on your follow-up visits.

१. धूम्रपान निषेध २. कूड़ा कर्कट केवल कूड़ेदान में ही डालें ३. थूकिये नहीं

(R) Recurrent gp-D RB

(L) WNL

दिनांक - Date

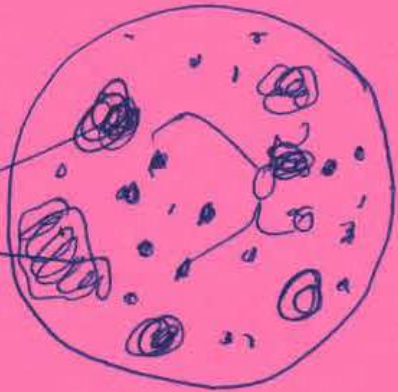
उपचार - Treatment

(R)

(L)

Sphere type vitreous seeds.

WNL



Active vitreous seeds (+)

active mass (+)

(R) Inj Topotecan 2mg/3mg given periocularly in IN quadrant.

Adv

(R) IAC - triple regimen.

(115) antkid

Sister Sophie to please. Co-ordinator P.

(B2) - 4D Mycin TDS X 5 days

only Sr. VI

नेत्र ईश्वरीय सर्वश्रेष्ठ उपहार है जिनका मनुष्य जीवन में दान करना परमश्रेष्ठ है।

इनकी पूर्ण रक्षा कीजिए ताकि ये आपकी रक्षा कर सकें।

Eyes are God's most precious gift to man kind and eye donation is the most noble deed.

Take full care of them so that they can take care of you.



Case fixed on 10.7.2021

ब. रो. वि. कार्ड
O.P.D. Card

डा. राजेन्द्र प्रसाद नेत्र विज्ञान केन्द्र
अ. भा. आयु. सं., नई दिल्ली - 110029

Dr. Rajendra Prasad Centre for Ophthalmic Sciences
A.I.I.M.S., New Delhi-110029



अनुभाग व दिन
Section and Day VI
बुधवार व शनिवार
Wednesday & Saturday

9772583292

कमरा नंबर
Cabin No.

यू.एच.आई.डी. संख्या
UHID No. 1049 49 855

आचार्य राधिका टंडन का एकक
Prof. Radhika Tandon's Unit

रोगी का नाम Name of the Patient	पुत्र/पुत्री/पत्नी S/D/W	लिंग Sex	आयु Age	पता Address
NAKSH GOSWAMI				

दिनांक DATE	निदान DIAGNOSIS	उपचार Treatment
	(R) Recurrent group D Rh (D) WNL	

29/6/21

EVA by DA lomi & U-VI

No of chemo cycles (10)

last chemo - 2/01/21

EBRT (-)

IA (M + T) - 24/2/21.

last EVA - 19/3/21.

Periocular Topo → 2/9/20
→ 6/11/20
→ 4/12/20

Periocular riv -
Topo → 22/1/21

(R) TTT - 7/7/2020

कृपया इस कार्ड को सुरक्षित रखें तथा अस्पताल में दिखाने के समय हर वक्त साथ लायें।

Kindly keep this Card safely and bring it on your follow-up visits.

- धूम्रपान निषेध 1. No Smoking
- कूड़ा कर्कट केवल कूड़ेदान में ही डालें 2. Use Dustbin
- थूकिये नहीं 3. No Spitting

ब० रो० वि० कार्ड
O.P.D. Card



नेत्र अमृत्यु उपहार है
जो आप ही दे सकते हैं

अनुभाग व दिन
Section and Day
बुधवार व शनिवार
Wednesday & Saturday

कमरा नंबर
Cabin No.

डा० राजेन्द्र प्रसाद नेत्र विज्ञान केन्द्र,
अ० भा० आयु० सं०, नई दिल्ली - ११००२९
Dr. Rajendra Prasad Centre for Ophthalmic Sciences
A.I.I.M.S., New Delhi-110029

यु एच आई डी संख्या
UHID No.

आचार्य राधिका टंडन का एकक
Prof. Radhika Tandon's Unit

रोगी का नाम Name of the patient	पुत्र/पुत्री/पत्नी S/D/W	लिंग Sex	आयु Age	पता Address
Naksh Gaswami				

दिनांक DATE	निदान DIAGNOSIS
	Intra-arterial chemotherapy.

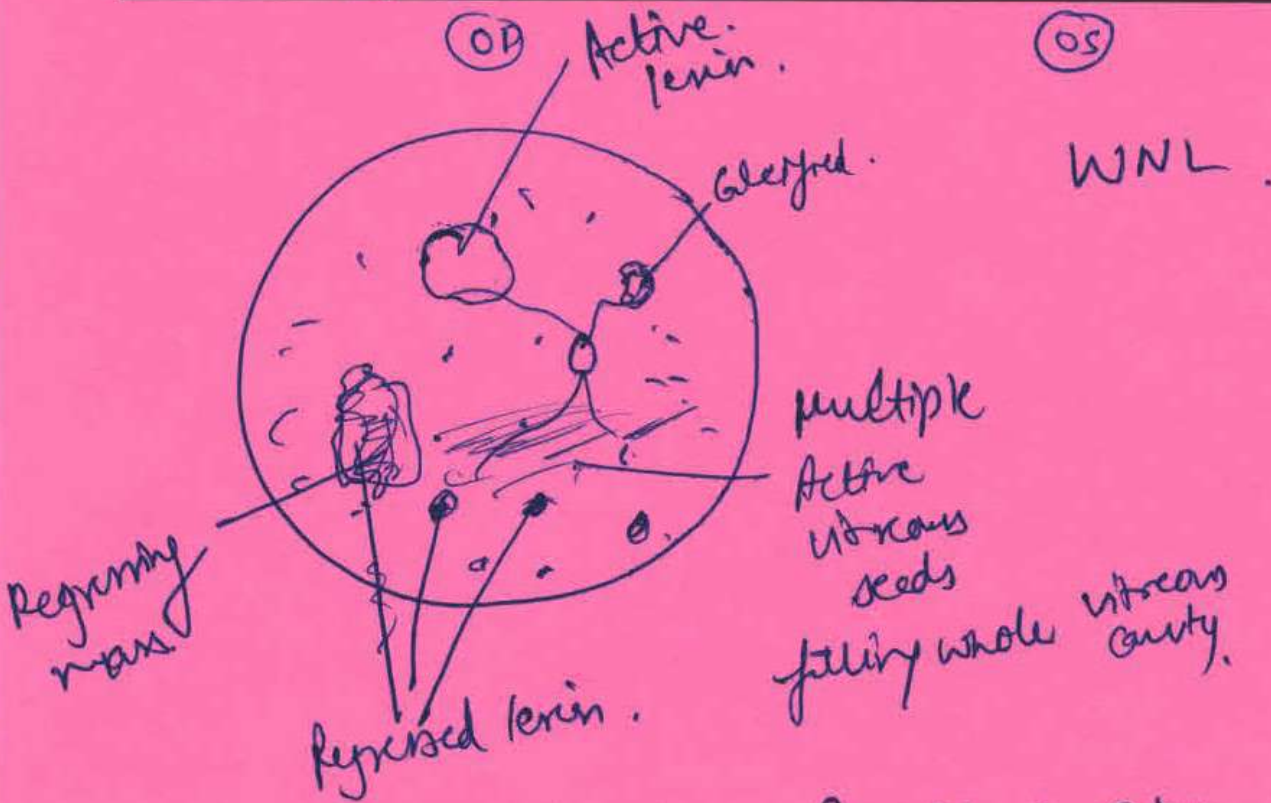
दिनांक DATE	उपचार Treatment
06/08/21	Refer to neuro radiology, 10B for date of IAC. (OPD - Thursday - 9am R. No. - 20) C. P. Centre.
	Admission - Dr. Neha, Unit - 6. R. P. Centre.
6/8/21	Provisionally planned for IAC (triple drug) on 16/9/21 please admit pt on 15/9/21 with negative RFAAR

कृपया इस कार्ड को सुरक्षित रखें तथा अस्पताल में दिखाने के समय हर वक्त साथ लायें।
Kindly keep this Card safely and bring it on your follow-up visits.

१. धूम्रपान निषेध २. कूड़ा कर्कट केवल कूड़ेदान में ही डालें ३. थूकिये नहीं

दिनांक - Date 6/08/21

उपचार - Treatment



Adv

(R) Sry Topotecan 2mg/2ml given periodically

(R) [E/D Moxi-KT (4) E/D Tear drops - (4)] x 1 week

(L) - E/D Mycin TDS (2) x 5 days

Syp PCM 5ml B D x 5 days.

(115) Sister Jyoti (R) IAC - triple regimen. (Melfalan + Topotecan + Carboplatin).

नेत्र ईश्वरीय सर्वश्रेष्ठ उपहार है जिनका मनुष्य जीवन में दान करना परमश्रेष्ठ है। इनकी पूर्ण रक्षा कीजिए ताकि ये आपकी रक्षा कर सकें।

Eyes are God's most precious gift to man kind and eye donation is the most noble deed.

Take full care of them so that they can take care of you.

mehy 6/8/2021

VAC (115) Anurag + 90m

ब. रो. वि. कार्ड
O.P.D. Card



अनुभाग व दिन
Section and Day VI
बुधवार व शनिवार
Wednesday & Saturday

कमरा नंबर
Cabin No.

डा. राजेन्द्र प्रसाद नेत्र विज्ञान केन्द्र
अ. भा. आयु. सं., नई दिल्ली - 110029

Dr. Rajendra Prasad Centre for Ophthalmic Sciences
A.I.I.M.S., New Delhi-110029

यू.एच.आई.डी. संख्या

आचार्य राधिका टंडन का एकक

UHID No. 104949855

Prof. Radhika Tandon's Unit

रोगी का नाम Name of the Patient	पुत्र/पुत्री/पत्नी S/D/W	लिंग Sex	आयु Age	पता Address
Naksh Goswami				

दिनांक DATE	निदान DIAGNOSIS
	(R) Regramin Group D RR. (L) WNL

उपचार Treatment

06/08/21

EUA done by Dr. ~~Radhika Tandon~~ ^{Tom} & Unit 6

No chemo cells - (0)

- Last chemo date - 20/07/21

- EBRT (0)

- IAC - (2) 24/2/21 10/7/21 Periocular topotecan

- Periocular (intraorbital) inf 2/9/20
- 6/11/20
- 4/12/20
- 29/6/21

- Last EUA date = 26/9/21

Periocular topotecan

कृपया इस कार्ड को सुरक्षित रखें तथा अस्पताल में दिखाने के समय हर वक्त साथ लायें। 22/1/21

Kindly keep this Card safely and bring it on your follow-up visits.

1. धूम्रपान निषेध
2. कूड़ा कर्कट केवल कूड़ेदान में ही डालें
3. थूकिये नहीं
1. No Smoking
2. Use Dustbin
3. No Spitting



GOYAL MRI & DIAGNOSTIC CENTRE

B-1/12, SAFDARJUNG ENCLAVE, NEW DELHI - 110029

Phone : 40771234, 26107559 E-mail : goyalmri@yahoo.com

Dr. Rajesh Kapur
MD, DNB (Radio Diagnosis)

Dr. Ankur Gadodia
MD (AIIMS), DNB, FRCR

Dr. Pranay R Kapur
MBBS, DNB

11.12.2019

MAST. NAKSH GOSWAMI, 2YRS / M UID: 12.19.0639

M.R. OF THE CRANIUM WITH CONTRAST

Axial T1, FLAIR & FSE T2 weighted scans of the brain were studied and these were correlated with coronal and sagittal FSE T2 weighted scans. Additional T1 weighted axial, coronal & sagittal scans were obtained following administration of contrast (10mL Omniscan). No adverse contrast reaction was noted till 30 minutes after the contrast injection.

12 x 16mm well defined mass lesion is seen in the posterior chamber of the right globe along the lateral aspect. Lesion shows hypointense signal on T1 and T2 weighted images and displays homogeneous enhancement following administration of contrast. No extraocular extension is seen. Right optic nerve is unremarkable. Findings are suggestive of retinoblastoma.

Left globe and left optic nerves are unremarkable.

The optic chiasm, infundibulum and pituitary gland do not show abnormality.

Cerebral and cerebellar parenchyma is unremarkable.

Bilateral basal ganglia and thalami are normal in signal intensity.

The corpus callosum, sellar and suprasellar regions, and skull base are normal. No midline shift. No acute intracerebral hemorrhage.

Posterior fossa and brainstem are unremarkable. Skull base arteries demonstrate normal flow void.

Mucosal thickening is seen in bilateral maxillary sinuses. Fluid / mucosal thickening is seen within bilateral mastoid air cells (? Mastoiditis).

IMPRESSION:

- **12 x 16mm well defined homogeneously enhancing mass lesion in the posterior chamber of the right globe along the lateral aspect. No extraocular extension is seen. Right optic nerve is unremarkable. Findings are suggestive of retinoblastoma.**

Clinical and histopathological correlation is necessary

This is a professional opinion and not the diagnosis. Findings should be clinically correlated.

DR. ANKUR GADODIA

MD (AIIMS), DNB, FRCR (UK)

Facilities Available : 3.0 Tesla GE Pioneer MRI, 32 Slice CT Scan, Bone Densitometry (DEXA), Doppler, Digital X-Ray, Echocardiography, ECG, PFT, EEG, NCV, EMG, Pathology Lab (NABL & NABH Accredited)

Retinoblastoma

DEPARTMENT OF NEURORADIOLOGY
N S CENTRE, A.I.I.M.S.

PATIENT'S NAME :- Nalini Goswami OPD / WARD _____

OPD / CR NO. _____ NR NO. _____

LIST OF COMMON CONSUMABLES ITEMS FOR ANGIOGRAPHY / EMBOLIZATION

- ✓ 1. Injection Omnipaque 300 mg/ Iomeron 300mg 200ml
- 2. Inj. Omniscan 20ml 2 vials
- ✓ 3. Three way Connector (BD) 6 pcs
- 4. E C G Electrodes 6 pcs
- 5. I. V. Infusion set (B.Braun) 3 sets
- 6. Normal Saline (Polypack) 500ml 3 nos.
- ✓ 7. Short Connecting Tube with Three way 2 nos.
- ✓ 8. Long Connecting Tube with Three way 2 nos.
- 9. Luer Lock Glass van syringes 10ml 4 nos.
- 10. Sterile Disposable Gloves Size 7 10 nos.
- ✓ 11. Medicut 18G 1 no.
- ✓ 12. Inj. Protamin 1 no.
- 13. Inj. NTG - Pilsad 5P - ① 1 amp.
- ✓ 14. Inj. Nimodipin 1 amp.
- ✓ 15. Exchange Guide wire (TERMO) 260cm 35/38 1 no.
- 16. Neuro Intervention disposable KIT 1 Pkt.
- 17. Single Y Connector (MERIT) 2 nos.
- ✓ 18. Double large bore Y Connector (MERIT) 2 nos.
- ✓ 19. Femoral Sheath (Arrow) 6F/7F/8F 5F 1no./2 nos.
- 20. Inflation Device (Encore) 1 no.

Aash
9654 887585
9953034293.

9910119136, 9871584.

21. Marathan - ① Evg - 72900 22800, 98711 88632

22. Hybrid .0.000 - ① Balt. - 847 00 33411

23. Envoy 5F - ① Cotman - 88 26072222 .

24. Drugs .
Mephalar - ①
Tosotecan - ①
Carboplam - ①

सेवा में,

CHILD Helping Hand
B-28, MAURYA COMPLEX
LAXMI NAGAR
DELHI-110092

आदरणीय

मेरे बच्चे का नाम नरु गौड़ानी है
इसकी UMRD NO. 104949855 है इसकी रेटिनोएन्तास्टीमा बीमारी
है। इसका इलाज संस्था से चल रहा है। बच्चे को 2
IAC पट्टे हैं, चुकी है जो मैं अपने पैसा से कराई भी
उन्की डॉक्टर ने बीमारी IAC Plann की है उन्की में अपॉस
नहीं कर सकता जिसके लिए मुझे आर्थिक मदद की
आवश्यकता है, CHILD HELPING HAND NGO की टीम से इस IAC
में Support मिल रहा है धन्यवाद

Name - Avinash Goswami
Mob - 9772583292

patient is very
poor and need
IAC support
from you.
Kindly help

डॉ. निवेदिता लोमी / Dr. NEWETE LOMI
सहायक आचार्य / Assistant Professor
डॉ. राजेन्द्र प्रसाद नेत्र विज्ञान केंद्र
Dr. N. P. Centre for Ophthalmic Sciences
आ. 2/2021 डॉ. विवेका / A.M.M.S., New Delhi-29
6/9/2021